Mastocytosis 118

Michael D. Tharp

Key features

- Mastocytosis can develop from birth to adulthood and may involve only the skin (most children and some adults) or multiple organs such as the bone marrow, liver, spleen, and/or lymph nodes (primarily adults)
- Childhood disease is more common and often presents with one or more tan to pink–brown or brown papules or plaques (maculopapular mastocytosis) that frequently resolve by adolescence
- Mastocytomas are thicker plaques or nodules that are few in number and occur primarily in children
- Adults with mastocytosis often have cutaneous lesions; when present, they typically appear as small red–brown macules or papules ("urticaria pigmentosa") and tend to be associated with milder disease
- Adult mastocytosis persists throughout life
- Stroking of mastocytosis lesions often leads to urtication (Darier sign), which is more pronounced in children due to a higher density of mast cells
- Activating mutations in codon 816 of *KIT* are detected in the majority of adults and ~40% of children with mastocytosis; extracellular domain mutations occur more often in childhood-onset than in adult-onset disease
- Patients may have accompanying symptoms of mast cell mediator release such as pruritus, flushing, headaches, abdominal pain, diarrhea, and syncope
- Treatment is primarily directed at controlling symptoms in patients with limited disease and inhibiting activating *KIT* mutations in those with more advanced disease

INTRODUCTION

Mastocytosis represents a spectrum of clinical disorders with a common phenotype of tissue mast cell hyperplasia that can involve the skin, bone marrow, and other organs. Despite significant advances in understanding the pathogenesis of mastocytosis, explanations for the differences in clinical presentations and course between childhood-onset and adult-onset disease are still needed (Fig. 118.1). Childhood mastocytosis has an excellent prognosis, with ~50%–70% of affected children experiencing resolution by adolescence. In contrast, adult-onset mastocytosis typically has a chronic course and is more often associated with extracutaneous involvement and systemic symptoms[1]. Therapy for mastocytosis usually centers on inhibiting the effects of secreted mast cell mediators[2–4], with tyrosine kinase inhibitors such as midostaurin, avapritinib, and imatinib representing options in patients with more advanced systemic disease[5–8]. Cytoreductive therapies (e.g. cladribine) and rarely hematopoietic stem cell transplantation may also be utilized in advanced systemic disease[4].

HISTORY

The original description of mastocytosis was by Nettleship and Tay, who told of a 2-year-old girl with hyperpigmented papules that spontaneously urticated[9]. Eight years later, in 1877, Paul Ehrlich formally discovered the mast cell. The next year, Sangster suggested the name "urticaria pigmentosa". Unna was the first to demonstrate that mast cells were responsible for the cutaneous findings in mastocytosis patients[10].

EPIDEMIOLOGY

Mastocytosis can be present at birth or develop any time thereafter, including into late adulthood. Childhood-onset mastocytosis is defined as presenting prior to puberty. In a pediatric series (n=101), cutaneous mastocytosis appeared by ages 6 months and 2 years in 73% and 97% of children, respectively[11]. Adult-onset mastocytosis most often develops in the third or fourth decade of life, has no sex preference, and occurs in all races[12,13].

While most individuals with mastocytosis have no family history of the disorder, there have been over 70 familial cases reported, including at least 15 sets of monozygotic twins; however, twin pairs discordant for the disease have also been described. Mastocytosis has been documented in three generations of a single kindred[14,15].

PATHOGENESIS

Mast cells are derived from pluripotent $CD34^+$ precursors in the bone marrow that then circulate in the peripheral blood as agranular, monocytic-appearing cells. After migrating into tissues, these immature mast cells assume their typical granular morphology (see Ch. 18). Circulating mast cell precursors express CD34, the tyrosine kinase receptor KIT (CD117), and IgG receptors (FcγRII), but not high-affinity IgE receptors (FcεRI)[16]. The KIT receptor is expressed on mast cells, melanocytes, primitive hematopoietic stem cells, primordial germ cells, and interstitial cells of Cajal. Activation of KIT by its ligand (stem cell factor [SCF]) induces mast cell growth and maturation, and it extends cell survival by preventing apoptosis. Membrane-bound and soluble forms of SCF exist, and both induce KIT activation. SCF is produced by bone marrow stromal cells, fibroblasts, keratinocytes, endothelial cells, and reproductive Sertoli and granulosa cells. Peripheral blood mast cell precursors cultured in the presence of SCF and other cytokines (e.g. interleukin [IL]-3, -4, -6, -9) become $KIT^+/CD34^-/Fc\gamma RII^-/Fc\varepsilon RI^+$ and develop characteristic cytoplasmic mast cell granules, as seen in mature tissue mast cells[16,17].

Alterations in KIT structure and activity are central to the pathogenesis of mastocytosis. *Somatic* activating mutations in *KIT* involving codon 816 represent the most common genetic abnormality in patients with sporadic mastocytosis. The result is a substitution of the amino acid aspartic acid (D) with valine (V), i.e. D816V, or less commonly another amino acid (Fig. 118.2). These mutations lead to constitutive, ligand-independent activation of the receptor. Less common activating mutations and a rare dominant inactivating mutation have also been identified in children and adults with mastocytosis (see Fig. 118.2). In addition, rare *germline* mutations have been reported[15,18–20].

In a study in which the entire *KIT* sequence was analyzed in skin biopsy specimens from 50 children (ages 0–16 years) with primarily maculopapular mastocytosis, codon 816 mutations were found in 42% and other activating mutations in 44% of the patients[18]. However, the mechanism by which childhood disease often resolves spontaneously, despite the presence of underlying somatic *KIT* mutations, remains unknown[14,18].

In a transgenic mouse model of mastocytosis in which human activated *KIT* (D816V) was expressed, only 8 of 28 genetically identical animals developed clinical features of mastocytosis, ranging from indolent mast cell hyperplasia to an invasive mast cell tumor[21]. In another model utilizing the homologous mouse *Kit* D814V, results ranged from advanced mast cell disease when this mutation appeared in undifferentiated bone marrow progenitors to variable mast cell tumors/skin disease when *Kit* D814V was only expressed in committed mast cell progenitors or mature mast cells[22]. The diverse phenotypic expression of gain-of-function *KIT* mutations, along with the lack of *KIT* mutations in some patients and families with mastocytosis, points to

Downloaded for Anonymous User (n/a) at Egyptian Knowledge Bank from ClinicalKey.com by Elsevier on March 10, 2024. For personal use only. No other uses without permission. Copyright ©2024. Elsevier Inc. All rights reserved.

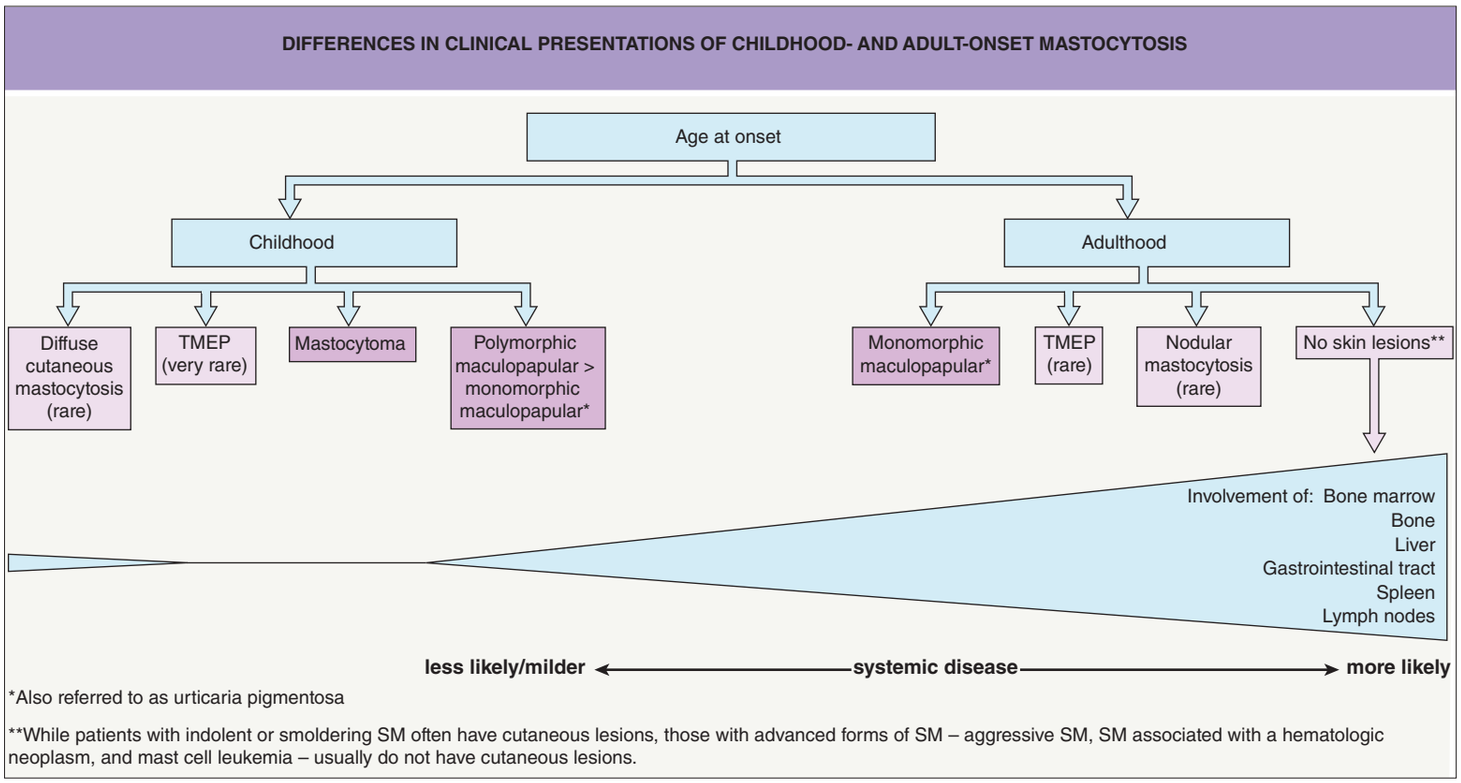

Fig. 118.1 Clinical presentations of childhood and adult-onset mastocytosis. The darker boxes represent the most common forms. Based upon the WHO classification scheme (see Tables 118.1 & 118.2), most children and a small proportion of adults have isolated cutaneous mastocytosis. Most adults with skin lesions have indolent systemic mastocytosis (SM), while those with advanced forms of SM usually do not have cutaneous involvement. In general, children have a benign course with a tendency for spontaneous remission. SM, systemic mastocytosis; TMEP, telangiectasis macularis eruptive perstans.

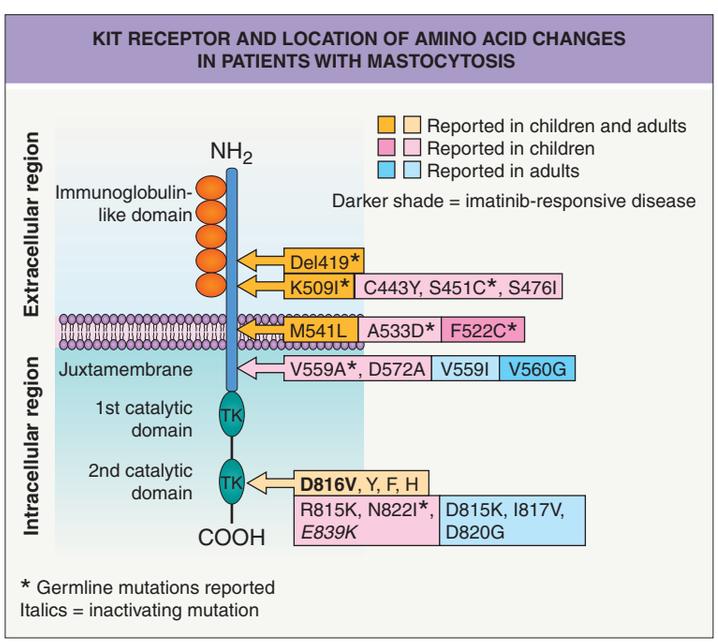

Fig. 118.2 KIT receptor and location of amino acid changes (due to *KIT* mutations) in pediatric and adult patients with mastocytosis. For example, D816V means that a mutation in codon 816 resulted from valine (V) being replaced by aspartic acid (D). The plasma membrane-bound KIT receptor is composed of three distinct regions: (1) the extracellular region (five immunoglobulin-like repeats [orange]); (2) the transmembrane region; and (3) the intracellular region (two tyrosine kinase domains [green]). The most common site for activating mutations is exon 17, which contains codon 816. The result is constitutive ligand-independent activation of the receptor. TK, tyrosine kinase domain (one binds ATP and the other has phosphotransferase activity).

additional pathogenic factors in mastocytosis. Indeed, in adult patients with advanced systemic mastocytosis, somatic mutations have been identified in *KIT* plus a variety of other genes such as *TET2, ASXL1, JAK2, SRSF2, RUNX1*, and *CBL*, which encode *Tet* methylcytosine dioxygenase *2*, *a*dditional *sex* combs *l*ike *1*, transcriptional regulator, *J*anus *k*inase *2*, *s*erine and arginine *r*ich *s*plicing *f*actor *2*, runt related transcription factor 1, and *Cbl* proto-oncogene, respectively[23,24].

CLINICAL FEATURES

Signs and Symptoms

Many children and adults with cutaneous mastocytosis have few, if any, symptoms. When symptoms do occur, they are due to the diverse physiologic effects of secreted mast cell mediators, such as histamine, eicosanoids, and cytokines (Fig. 118.3). These complaints and findings may range from pruritus and flushing to abdominal pain and diarrhea to palpitations, dizziness, and syncope. Of interest is the relative absence of pulmonary symptoms in mastocytosis. Complaints of fever, night sweats, malaise, weight loss, bone pain, epigastric distress, and problems with mentation (cognitive disorganization) often signal the presence of systemic disease. There are even rare reports of deaths in children and adults in association with extensive mast cell mediator release[2,13,14].

Symptoms of mastocytosis can be exacerbated by exercise, heat, friction, or other trauma to skin lesions. In addition, alcohol, narcotics, salicylates and other nonsteroidal anti-inflammatory drugs (NSAIDs), polymyxin B, and anticholinergic medications have been implicated in precipitating symptoms of mastocytosis. Some systemic anesthetic agents may potentially induce anaphylaxis (see below)[12].

Cutaneous Lesions

Childhood-onset mastocytosis, which almost always affects the skin, has three major clinical presentations: (1) solitary or few (≤3) lesions, referred to as "mastocytomas": 15%–50% of patients; (2) multiple

Downloaded for Anonymous User (n/a) at Egyptian Knowledge Bank from ClinicalKey.com by Elsevier on March 10, 2024. For personal use only. No other uses without permission. Copyright ©2024. Elsevier Inc. All rights reserved.

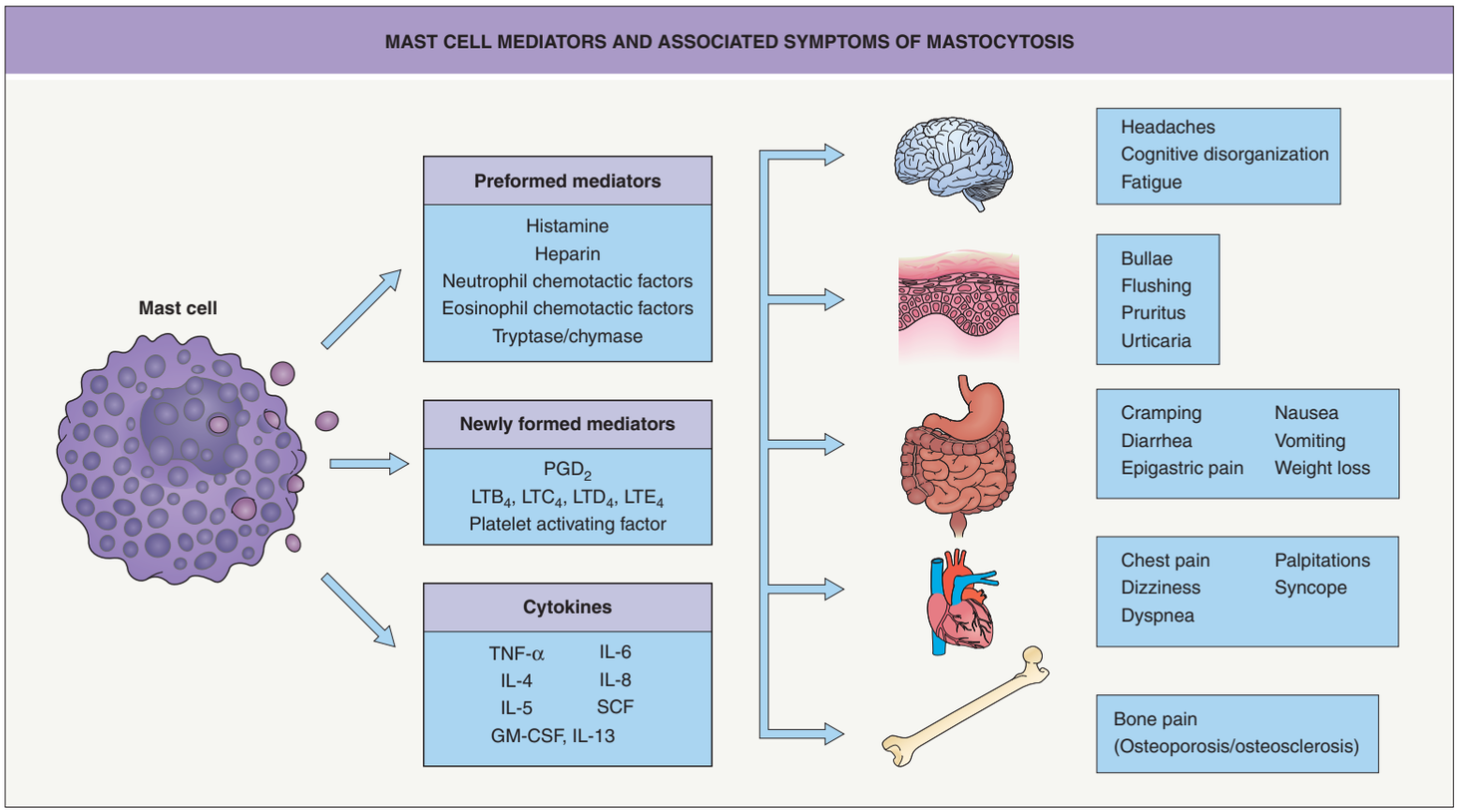

Fig. 118.3 Mast cell mediators and associated symptoms of mastocytosis. GM-CSF, granulocyte–macrophage colony-stimulating factor; IL, interleukins; LT, leukotrienes; PGD_2, prostaglandin D_2; SCF, stem cell factor; TNF, tumor necrosis factor.

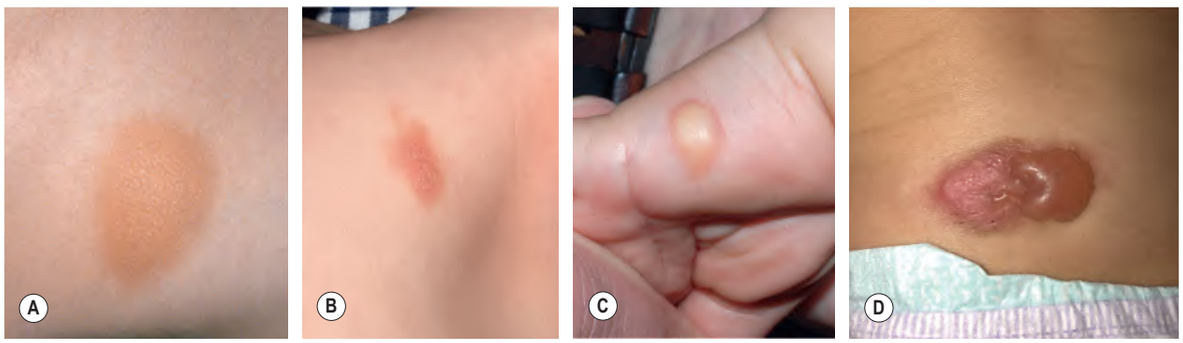

Fig. 118.4 Mastocytomas in young children. Tan (**A**) and pink–tan (**B**) plaques with a leathery surface. **C** Swelling and a subtle rim of erythema resulting from urtication of a yellowish nodule on the wrist. **D** Bullae formation within a pink–brown plaque on the back. *A, Courtesy Antonio Torrelo, MD; B–D Courtesy Julie V. Schaffer, MD.*

(<10 to >100) lesions, referred to as "maculopapular" mastocytosis: 45%–75% of patients; and (3) diffuse cutaneous involvement: <5%–10% of patients. A mastocytoma appears as a tan or yellow–tan to brown nodule or plaque, which may be only slightly elevated and typically has a leathery texture (Fig. 118.4). These lesions can be congenital or become evident during infancy, and they favor the distal extremities[11,12,14]. Bullae may arise within a mastocytoma, leading to misdiagnoses such as bullous impetigo.

Children with multiple lesions of mastocytosis most often present with *large, polymorphic* yellow–tan to pink–brown or brown plaques and nodules, which are frequently admixed with smaller lesions (Fig. 118.5D–F). This cutaneous variant is associated with an earlier onset during infancy and is more likely to spontaneously resolve[14,25]. Less often, only *small, monomorphic* tan to reddish-brown macules or papules are evident (Fig. 118.5A,B), similar to the typical urticaria pigmentosa presentation in adults (see below)[14]. Multiple lesions favor the trunk and classically spare the central face, palms, and soles.

Diffuse cutaneous mastocytosis presents within the first few months of life as thickened skin with a leathery texture and variable hyperpigmentation in a generalized distribution (Fig. 118.6); however, systemic disease is typically absent and spontaneous resolution usually occurs[26]. This term should be reserved for diffuse skin involvement rather than the confluence of individual lesions. Less common presentations of mastocytosis in children include ill-defined tan or telangiectatic patches; small, firm brown nodules; and yellowish patches with superimposed doughy papules ("xanthelasmoid" mastocytosis)[12].

Blistering following urtication is common in infants and young children with mastocytosis, especially those with large, thick lesions or the diffuse form. The latter patients may present with extensive bullae and erosions (see Fig. 118.6; see Ch. 34). The tendency to blister usually remits by 3 to 5 years of age, and it is believed to result from the release of mast cell serine proteases[14,17].

The most common cutaneous lesions of *adult-onset mastocytosis* are small (<1 cm), monomorphic, reddish-brown macules and papules (Fig. 118.7). This pattern is now referred to as maculopapular but the term urticaria pigmentosa is still commonly employed. In patients with skin type I, the macules and papules may appear pink to red in color. Lesions are most numerous on the trunk and proximal extremities and appear less frequently on the face, distal extremities, or palms and soles. Individual lesions can resolve, but the total number usually increases over time. Close inspection reveals variable hyperpigmentation and fine telangiectasias. These lesions are most often associated with indolent systemic mastocytosis[1,12] (see below).

Less commonly, yellow–tan to red–brown or violaceous nodules or papulonodules develop, representing a hallmark of indolent disease (see below)[12,27]. Severe infiltrative mastocytosis may progress to diffuse thickening of the skin, especially in flexural sites; facial involvement may acquire a leonine appearance. A rare form of cutaneous mastocytosis

Downloaded for Anonymous User (n/a) at Egyptian Knowledge Bank from ClinicalKey.com by Elsevier on March 10, 2024. For personal use only. No other uses without permission. Copyright ©2024. Elsevier Inc. All rights reserved.

Fig. 118.5 Maculopapular cutaneous mastocytosis in children. Patients can present with variable numbers and sizes of papules, which may be scattered (**A**), clustered (**B**), or nearly confluent (**C**), as well as predominantly plaques (**D, E**) or papulonodules (**F**). As in solitary lesions, the degree of associated hyperpigmentation can vary. Note the Darier sign (**C**, **D**). *A, C, Courtesy Antonio Torrelo, MD; B, D, E Courtesy Julie V. Schaffer, MD.*

Fig. 118.6 Diffuse cutaneous mastocytosis and blistering in infants. Diffusely infiltrated skin with multiple erosions and a leathery texture that may be subtle (**A**) or striking (**B**). This appearance has been compared to pigskin. **C** Spontaneous blister superimposed on a plaque. *A, Courtesy Antonio Torrelo, MD.*

is telangiectasia macularis eruptiva perstans (TMEP), which is characterized by macules and patches composed of telangiectasias without significant hyperpigmentation (Fig. 118.8). Mastocytomas are extremely rare in adults[1,12].

Formation of an urticaria-like wheal upon firmly stroking or rubbing of skin lesions (Darier sign) results from release of mast cell mediators and is indicative of the diagnosis (Fig. 118.9). Darier sign is readily demonstrated in pediatric patients, especially with nodular lesions, and if vigorously induced may precipitate systemic symptoms[11,14]. This sign tends to be more subtle in typical adult mastocytosis lesions and TMEP. These differences reflect lesional mast cell density, which is higher in mastocytomas and childhood maculopapular mastocytosis than in adult-onset cutaneous mastocytosis[28]. Dermographism may also be observed in the uninvolved skin of pediatric and adult mastocytosis patients[1,14,28].

Downloaded for Anonymous User (n/a) at Egyptian Knowledge Bank from ClinicalKey.com by Elsevier on March 10, 2024. For personal use only. No other uses without permission. Copyright ©2024. Elsevier Inc. All rights reserved.

Fig. 118.7 Adult maculopapular mastocytosis ("urticaria pigmentosa"). Numerous reddish-brown macules and papules.

Fig. 118.8 Telangiectasia macularis eruptiva perstans. Multiple lesions composed of telangiectasias are present.

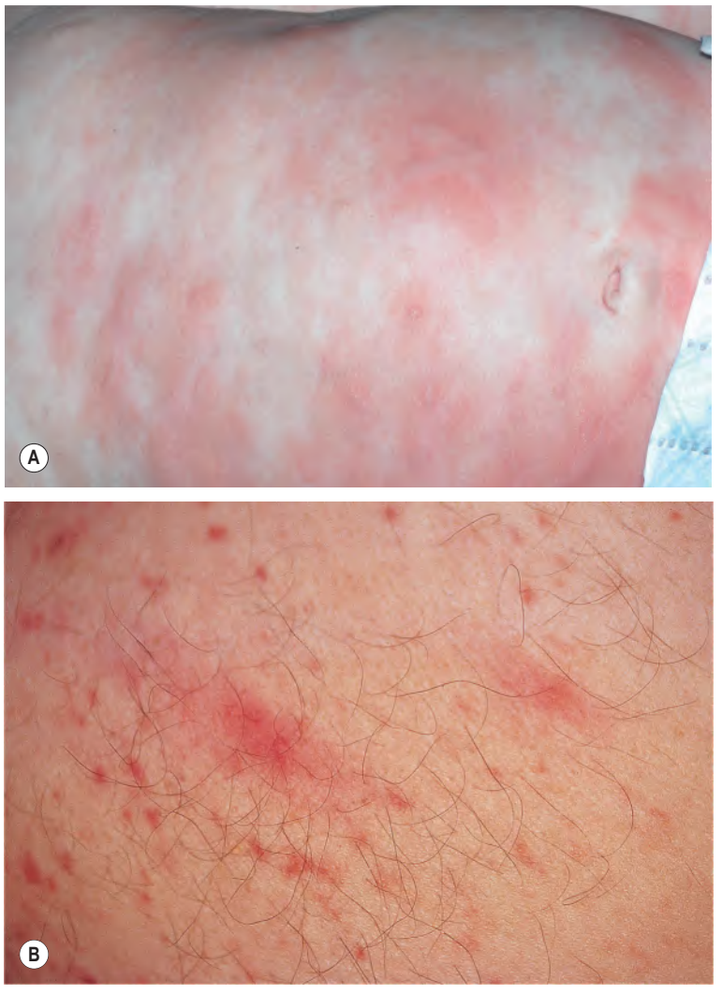

Fig. 118.9 Darier sign in mastocytosis. A An infant with extensive cutaneous involvement. **B** An adult with macular and papular lesions. *A, Courtesy Julie V. Schaffer, MD; B, Courtesy Thomas Horn, MD.*

Systemic Manifestations

Skeletal lesions frequently occur in adult patients with mastocytosis but are rare in children (see Fig. 118.1)[11,14]. Bone involvement can be associated with skeletal pain. In one study of 142 adults with mastocytosis, 40% had skeletal involvement, with a similar frequency in those with childhood-onset and adult-onset disease[29]. Bony lesions may appear as radio-opacities, radiolucencies, or a mixture of the two. The skull, spine, and pelvis are most commonly involved. In an earlier study of 58 adult systemic mastocytosis patients, 57% had diffuse bone involvement, whereas only 2% had focal lesions. Demineralization was the most common change in patients with diffuse skeletal disease, followed by osteosclerosis and mixed lesions of osteosclerosis and osteoporosis[30]. Osteoporosis is more prevalent in men with mastocytosis and may be the presenting manifestation of the disease[30,31].

Undecalcified iliac crest biopsies from adult mastocytosis patients have demonstrated increased numbers of mast cells and evidence of enhanced cortical and trabecular bone turnover. These observations led to the hypothesis that mast cells and their mediators are directly responsible for the associated skeletal changes. For example, mast cell-derived heparin and SCF have been implicated in promoting osteoporosis via stimulation of osteoclastic activity. Osteoclasts have been shown to express KIT receptors on their surface and to be activated by SCF. Mast cell histamine, however, is also capable of promoting bone sclerosis through activation of fibroblasts, and mast cell-derived IL-6 appears to induce both bone resorptive and fibrotic activities[30,32].

The **bone marrow** is involved in nearly all adult patients with systemic mastocytosis. In general, a bone marrow biopsy appears to be more reliable than an aspirate for identifying abnormal mast cell morphology and distribution[33]. Multifocal mast cell aggregates are typically located in perivascular and paratrabecular locations. Bone marrow involvement is relatively uncommon in children with mastocytosis, and bone marrow biopsy is not routinely recommended[14,34].

Splenomegaly is relatively common in patients with advanced systemic mastocytosis but rare in those with indolent systemic disease[35,36]. Increased numbers of mast cells and eosinophils are frequently observed in the spleen, as are various degrees of fibrosis and hematopoiesis. In general, **lymph node** enlargement is uncommon in mastocytosis patients but it does occur in those with more advanced systemic disease. Among 58 systemic mastocytosis patients, 26% had peripheral lymphadenopathy, whereas 19% had central nodal disease[37]. Histologically, early involvement of lymph nodes often consists of only clusters of mast cells, while in more advanced disease, mast cell infiltrates involve the paracortex and are often accompanied by eosinophils[37,38].

Gastrointestinal (GI) symptoms such as abdominal pain, diarrhea, nausea and vomiting resulting from mast cell mediator release may occur spontaneously or be precipitated by alcohol, aspirin, NSAIDs, or certain foods[36,39]. Approximately 25% of patients with isolated cutaneous disease and 70% of those with systemic mastocytosis report GI symptoms[39]. Diarrhea in patients with mastocytosis is usually episodic; it can result from malabsorption, increased motility, and/or acid hypersecretion, with the former due to mast cell infiltration and the latter two symptoms likely related to the release of mast cell histamine and prostaglandins. Patients with systemic mastocytosis are at increased risk of gastritis and peptic ulcers, which occasionally lead to

Downloaded for Anonymous User (n/a) at Egyptian Knowledge Bank from ClinicalKey.com by Elsevier on March 10, 2024. For personal use only. No other uses without permission. Copyright ©2024. Elsevier Inc. All rights reserved.

GI hemorrhage. A number of radiographic changes in the GI tract have been described, including urticaria-like lesions and thickened gastric, duodenal and jejunal folds, as well as mucosal nodules and/or peptic ulcers. Biopsies of mucosal nodules have demonstrated numerous mast cells with varying numbers of eosinophils[40]. Gastrointestinal stromal tumors (GISTs) frequently have underlying *somatic* activating KIT mutations and are occasionally seen together with cutaneous mastocytosis in families with *germline* activating *KIT* mutations (see Fig. 118.2)[41]. **Hepatomegaly** most commonly occurs in advanced systemic mastocytosis and is not always associated with abnormal liver function tests[35,36].

A mixed organic **brain** syndrome with a constellation of symptoms – including irritability, fatigue, headache, poor attention span and motivation, limited short-term memory, inability to work effectively, and difficulty in interacting with other people – has been described in patients with mastocytosis. It has been hypothesized that these symptoms may be secondary to mast cell mediators. Electroencephalographic studies in these patients range from normal to changes consistent with a toxic or metabolic process[42].

Classification of Mastocytosis

The World Health Organization (WHO) classification scheme for mastocytosis was proposed in 2001 and then modified in 2008 and 2016 (Table 118.1)[36]. *Cutaneous mastocytosis* represents the largest group and includes nearly all affected children and some adults. Childhood-onset mastocytosis resolves by adolescence in ~50%–70% of patients, with persistence into adulthood in the remainder[13,14]. The WHO has also established criteria for the diagnosis of *systemic mastocytosis* (SM; Table 118.2)[36]. From a dermatologic perspective, appreciation of indolent and smoldering SM is important as these patients frequently have cutaneous lesions.

Although patients with *indolent systemic mastocytosis* (ISM) have detectable mast cell infiltrates in multiple organs (e.g. bone marrow, liver, spleen, lymph nodes), organ impairment is generally absent and there are few, if any, systemic symptoms. Patients with ISM frequently have slightly increased numbers of spindle-shaped, hypogranulated bone marrow mast cells (BMMCs) that express CD25 ± CD2, which are not expressed in normal BMMCs. CD25 appears to be the most reliable marker for BMMCs with gain-of-function *KIT* mutations in exon 17 (see Fig. 118.2)[33,36]. Progression of ISM to more severe forms of SM appears to be unusual. In a study of 145 adults with ISM, the cumulative probabilities of disease progression to more advanced SM at 10 and 25 years were 1.7% and 8.4%, respectively[43].

Compared to individuals with ISM, patients with the *smoldering SM* (SSM) have increased disease burden manifesting as "B" findings – e.g. hepatosplenomegaly, lymphadenopathy, serum tryptase levels >200 ng/ml (see Table 118.2) – and are more likely to be anemic and an older age. The overall prognosis for SSM patients is less favorable than ISM due to an increased risk for developing more advanced systemic disease[43–46].

SM with an associated hematologic neoplasm (SM-AHN) does not usually present with cutaneous lesions, but affected individuals may have "B" and "C" findings (see Table 118.2). In some patients, the hematologic neoplasm precedes the development of SM. The overall prognosis of SM-AHN patients depends upon the severity of the hematologic disease[44,45].

Patients with *aggressive SM* (ASM) have "C" findings with organ dysfunction secondary to mast cell infiltrates, notably in the liver (e.g. ascites, portal hypertension), bone (pain, pathologic fractures), gastrointestinal tract (malabsorption), and spleen (hypersplenism) (see Table 118.2). They also may develop cytopenias, leukocytoses (eosinophilia, basophilia, monocytosis), and/or thrombocytosis as a reflection of abnormal myelopoiesis. Serum tryptase levels are often elevated, reflecting a significantly increased total body mast cell burden. The overall prognosis appears to depend upon the response to treatment (Fig. 118.10)[33,44,45].

Mast cell leukemia (MCL) is rare and is divided into acute and chronic forms. Diagnosis requires ≥10% mast cells among nucleated peripheral blood cells and ≥20% atypical mast cells in the bone marrow[1,36,44]. However, because mature mast cells are rarely observed in the blood

WHO 2016 CLASSIFICATION OF MASTOCYTOSIS
Cutaneous mastocytosis (CM)
• Maculopapular CM (urticaria pigmentosa) • Diffuse CM • Mastocytoma of skin (cutaneous mastocytoma)
Systemic mastocytosis (SM)
• Indolent SM* • Smoldering SM* • SM with an associated hematologic (non-mast cell lineage) neoplasm • Aggressive SM • Mast cell leukemia
Mast cell sarcoma
*Forms of SM most likely to have cutaneous involvement; see Table 118.2 for defining criteria.

Table 118.1 WHO 2016 classification of mastocytosis.

WHO CRITERIA FOR THE DIAGNOSIS OF SYSTEMIC MASTOCYTOSIS AND RELATED B & C FINDINGS
WHO criteria for systemic mastocytosis (SM)
Major criterion
Multifocal, dense infiltrates of MCs (aggregates of ≥15 MCs) in BM biopsies and/or in sections of other extracutaneous organ(s)
Minor criteria
• In BM smears, >25% of all MCs are atypical – *or* – >25% of MCs are spindle-shaped in infiltrates within extracutaneous organ(s) • *KIT* point mutation at codon 816 in the BM or another extracutaneous organ • MCs in BM, blood, or another extracutaneous organ express CD2 and/or CD25 • Baseline serum tryptase level >20 ng/ml (if there is an unrelated myeloid neoplasm, this is not valid as an SM criterion)
SM diagnosis requires either the major criterion plus 1 minor criterion or 3 minor criteria
Criteria for B and C findings in patients with SM
B findings: indicate a high burden of MCs and/or expansion of the neoplastic process into multiple hematopoietic lineages, without impairment of organ function
• MC infiltration of the BM >30% and basal serum tryptase level >200 ng/ml • Hypercellular BM with loss of fat cells, discrete signs of dysmyelopoiesis without substantial cytopenias, or WHO criteria for a myelodysplastic syndrome or myeloproliferative neoplasm • Organomegaly: palpable hepatomegaly with normal liver function, palpable splenomegaly without hypersplenism, and/or lymphadenopathy on palpation or imaging (>2 cm)
C findings: indicate organ damage produced by mast cell infiltration (should be confirmed on biopsy if possible)
• Cytopenia(s) caused by MCs: absolute neutrophil count <1000/mcl, hemoglobin <10 g/dl, or platelet count <100 000/mcl • Hepatomegaly with abnormal liver function, ascites, and/or portal hypertension • Splenomegaly with associated hypersplenism • Skeletal osteolytic lesions with pathologic fractures (fractures from osteoporosis alone is not a C finding) • Malabsorption with hypoalbuminemia and weight loss due to gastrointestinal MCs
In SM patients with <2 B findings and no C findings, the diagnosis is ***indolent SM****.* *When ≥2 B findings but no C findings are present, the diagnosis is* ***smoldering SM****.* *When ≥1 C findings (± B findings) are present, the diagnosis is either* ***aggressive SM*** *(<20% MCs in BM smears) or* ***MC leukemia*** *(≥20% MCs in BM smears)*

Table 118.2 WHO criteria for the diagnosis of systemic mastocytosis (SM) and related B & C findings. BM, bone marrow; MC, mast cell.

Downloaded for Anonymous User (n/a) at Egyptian Knowledge Bank from ClinicalKey.com by Elsevier on March 10, 2024. For personal use only. No other uses without permission. Copyright ©2024. Elsevier Inc. All rights reserved.

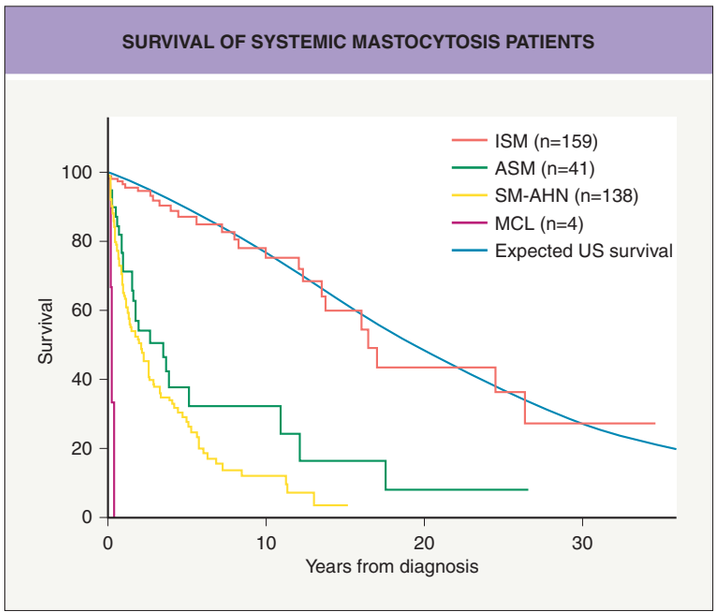

Fig. 118.10 Survival of patients with systemic mastocytosis (SM). The life expectancy of patients with indolent SM (ISM) was not significantly different from the age- and sex-matched US population from the appropriate time period, and leukemic transformation rarely occurred. Based upon these data, the authors recommended that, in general, therapy for ISM should be symptom-directed. ASM, aggressive SM; SM-AHN, SM with associated hematologic neoplasm; MCL, mast cell leukemia. *From Lim K-H, Tefferi A, Lasho TL, et al. Systemic mastocytosis in 342 consecutive adults: survival studies and prognostic factors. Blood 2009;113:5727–36.*

of normal individuals, their presence should raise the suspicion of an "aleukemic" form of MCL in which patients have fewer circulating mast cells[47]. Most MCL patients do not have cutaneous lesions, but those with an acute onset frequently exhibit "B" and "C" findings. Multi-organ failure, including of the bone marrow, often occurs over weeks to a few months in the acute form, with an expected survival of a year or less from the time of diagnosis[44,45]. Chronic MCL, however, has a more indolent course and survival is similar to SSM[47].

The presence of mutations in *KIT* and other genes may also have clinical implications in patients with mastocytosis. Advanced forms of mastocytosis are associated with gain-of-function *KIT* mutations in not only BMMC progenitors but also bone marrow mesenchymal stem cells, leading to involvement of lymphocytic or myeloid cell lineages[22,23,33,48]. In a study of 39 SM patients with a *KIT* D816V mutation, additional mutations in genes such as *TET2, SRSF2, ASXL1, RUNX1*, and *CBL* were found in 25% of those with ISM/SSM and 89% of those with more advanced forms of SM. These additional mutations were associated with decreased overall survival[24]. In contrast, patients with familial disease often lack *KIT* mutations in codons 815 and 816; their overall prognosis appears to be good but is less well defined[15,49].

An approach to the initial evaluation of a patient with cutaneous mastocytosis is presented in Fig. 118.11. A thorough history is crucial, with inquiries into the duration and progression as well as factors that provoke symptoms. For *childhood-onset* mastocytosis, the diagnosis is usually established clinically by recognition of characteristic skin lesions with a positive Darier sign (see Fig. 118.9). If the diagnosis is in doubt, confirmation can be achieved via a skin biopsy. No further testing is indicated for most children. However, additional evaluation should be performed in children who develop severe mast cell mediator-related symptoms or have evidence of hepatosplenomegaly, with the latter representing a marker of systemic involvement[14,50] (see Fig. 118.11).

Dermatologists have an opportunity to make the initial diagnosis of mastocytosis in adults who have cutaneous involvement, which can be confirmed by a skin biopsy demonstrating increased numbers of mast cells and/or the presence of an activating *KIT* mutation. Most of these patients have ISM, with fewer individuals having isolated cutaneous disease. For adults with skin lesions of mastocytosis, a baseline CBC with differential, serum tryptase level, liver function tests (LFTs), and DEXA scan of the lumbar spine and femur should be performed (see Fig. 118.11).

Recent guidelines from the American Initiative in Mast Cell Diseases (AIM) and European Competence Network on Mastocytosis (ECNM) recommend complete staging including a bone marrow biopsy in all adult mastocytosis patients to assist with prognostication[1,33,44,51]. However, other clinicians (including the author) do not believe that a bone marrow biopsy is required in adults with cutaneous lesions who have a normal or slightly elevated serum tryptase level[4] as well as a normal CBC and normal LFTs[50]. Of note, there is agreement that a bone marrow biopsy is indicated in those who have B or C findings (see Table 118.2)[1,44,50,51]. Detection of the *KIT* D816V mutation in the peripheral blood can help to determine the likelihood of SM and follow disease progression over time[52,53]. A provisional diagnosis of "mastocytosis in the skin" is given to adults with skin lesions of mastocytosis in whom a bone marrow biopsy has not been performed, and a scoring system has been developed to assess the risk of SM in these individuals[51,54] (see Fig. 118.11).

PATHOLOGY

Direct Studies

The diagnosis of mastocytosis is established by the presence of characteristic mast cells in one or more organs. For patients with cutaneous lesions, an increased number of mast cells can be demonstrated in a biopsy of lesional skin (Fig. 118.12). Eosinophils may be found within the dermis; hyperpigmentation of the basal layer of the epidermis with a few melanophages in the upper dermis is a common finding. Special stains, such as toluidine blue, Leder, and Giemsa, or monoclonal antibodies that recognize CD117 (KIT) or tryptase are helpful in identifying tissue mast cells[1] (Fig. 118.13).

Mast cell densities in childhood maculopapular mastocytosis and mastocytomas are 40-fold and 150-fold higher than in normal skin, respectively, and are therefore relatively easy to identify. In comparison, the density is ~30% lower in adults[28]. For nodular, papular, and macular lesions (including TMEP) of mastocytosis, mast cells have been quantified using a morphometric technique and shown to have densities of 63.2% (± 8.2% SEM), 16.1% (± 4.8% SEM), and 3.5% (± 1.8% SEM), respectively, compared to 0.4% (± 0.1% SEM) in normal skin[28]. In childhood mastocytosis, mast cells in lesional skin typically have a round or cuboidal shape, whereas they tend to appear fusiform or dendritic in adults. *KIT* mutations can often be detected in lesional skin and may help to confirm the diagnosis[18].

Biopsies of normal-appearing skin from patients with mastocytosis have normal concentrations of mast cells and thus are not useful for diagnosis[28]. A biopsy of the GI tract or bone marrow may be indicated in patients with mast cell mediator-related symptoms who lack skin lesions. Increased mast cell numbers in association with variable numbers of eosinophils can be observed in GI biopsies[1,33,39,50]. The bone marrow of patients with systemic disease frequently shows multifocal, spindle-shaped mast cells that express CD25 ± CD2. The detection of >25% atypical mast cells in extracutaneous tissues and the expression of CD25 and/or CD2 represent minor WHO diagnostic criteria for SM (see Table 118.2). Although coexpression of CD30 in BMMCs was initially reported to predict more advanced mastocytosis, a study of 142 patients demonstrated similar CD30 positivity across all systemic mastocytosis subgroups[55]. Because mast cells may appear hypogranular in tissues of patients with systemic disease, the combination of monoclonal antibodies against CD117 (KIT) and tryptase may be useful for their identification[36,56].

Indirect Studies

Detection of circulating mast cell mediators and/or their metabolites can offer indirect evidence of mastocytosis. Two forms (α and β) of mast cell tryptase have been identified[1,57]. Serum α-tryptase levels are elevated in patients with SM, regardless of whether or not they are experiencing acute symptoms, and therefore may be useful in assessing total body mast cell burden. However, β-tryptase is often detected both in mastocytosis patients and in patients *without* mastocytosis who are experiencing anaphylactic symptoms. Total (α and β) serum tryptase levels correlate with the extent of mast cell disease. In one study, half of those patients with total serum tryptase levels between 20 and 75 ng/ml had evidence of SM, whereas all patients

Downloaded for Anonymous User (n/a) at Egyptian Knowledge Bank from ClinicalKey.com by Elsevier on March 10, 2024. For personal use only. No other uses without permission. Copyright ©2024. Elsevier Inc. All rights reserved.

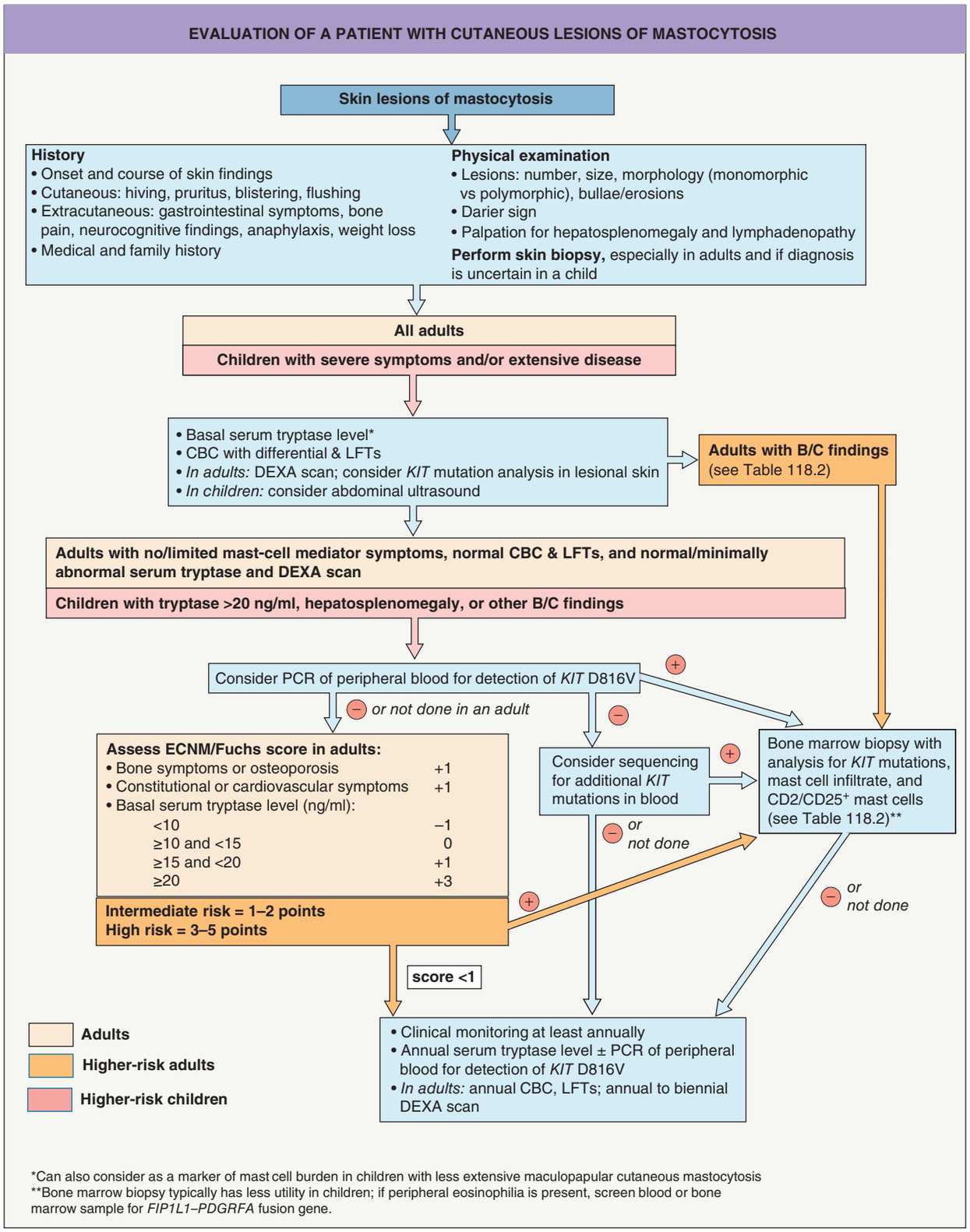

Fig. 118.11 Evaluation of a patient with cutaneous lesions of mastocytosis. Diagnosis of mastocytosis in the skin requires one major criterion – clinically typical skin lesions associated with the Darier sign – plus one minor criterion. The minor criteria are: (1) increased number of mast cells in lesional skin; and (2) detection of an activating *KIT* mutation in lesional skin. Additional investigations can be performed as directed by extracutaneous findings.

with levels >75 ng/ml had systemic involvement[5,57]. Of note, a total serum tryptase level >20 ng/ml represents one of the minor criteria for SM (see Table 118.2)[36].

Urinary excretion of histamine, MeImAA (1,4-methylimidazole acetic acid [histamine's major metabolite that is more persistently elevated]), and PGD_2M (major prostaglandin D_2 metabolite) are historical markers of mastocytosis disease that have low sensitivity and specificity. Plasma levels of IL-6 are also elevated in patients with mastocytosis, correlating with severity of bone marrow pathology, organomegaly, and extent of skin involvement[58].

DIFFERENTIAL DIAGNOSIS

The lesions of childhood and adult mastocytosis are so characteristic that they are only occasionally confused with other skin disorders. Mastocytomas may be misdiagnosed as café-au-lait macules, arthropod bites, Spitz or congenital melanocytic nevi, pseudolymphomas, or juvenile xanthogranulomas[11,14,49]. Childhood maculopapular lesions that spontaneously urticate may be mistaken for urticaria but are distinguished by the associated hyperpigmentation. The differential diagnosis for blisters due to mastocytosis in children may include bullous

Downloaded for Anonymous User (n/a) at Egyptian Knowledge Bank from ClinicalKey.com by Elsevier on March 10, 2024. For personal use only. No other uses without permission. Copyright ©2024. Elsevier Inc. All rights reserved.

arthropod bites, bullous impetigo, herpes simplex viral infection, linear IgA bullous dermatosis and, less often, other autoimmune bullous dermatoses. Infants with diffuse cutaneous mastocytosis can develop widespread blisters, which may be mistaken for epidermolysis bullosa or toxic epidermal necrolysis. Demonstration of increased mast cells in either the blister fluid or a skin biopsy helps to establish the diagnosis of mastocytosis. Nodular scabies in children has occasionally been misdiagnosed as mastocytosis.

The smaller maculopapular lesions typical of adult mastocytosis may at first glance appear as lentigines or melanocytic nevi, but mastocytosis lesions usually have associated erythema[56]. The differential diagnosis of TMEP includes other telangiectatic conditions, but some hyperpigmented maculopapular lesions are often evident. Lastly, if mast cells are not readily detected due to the presence of other leukocytes within the dermis, the patient may be misdiagnosed as having a histiocytic disorder or vasculitis[59].

Mast cell activation syndrome (MCAS) is characterized by symptoms of mast cell mediator release, but unlike mastocytosis there is no evidence of mast cell proliferation or persistent skin lesions. Serum tryptase levels may be slightly elevated in MCAS, and treatment with antihistamines, leukotriene inhibitors, and/or omalizumab is often of benefit[2,3]. Of note, the term mast cell activation *disorders* is sometimes used to encompass the various forms of mastocytosis and MCAS[60].

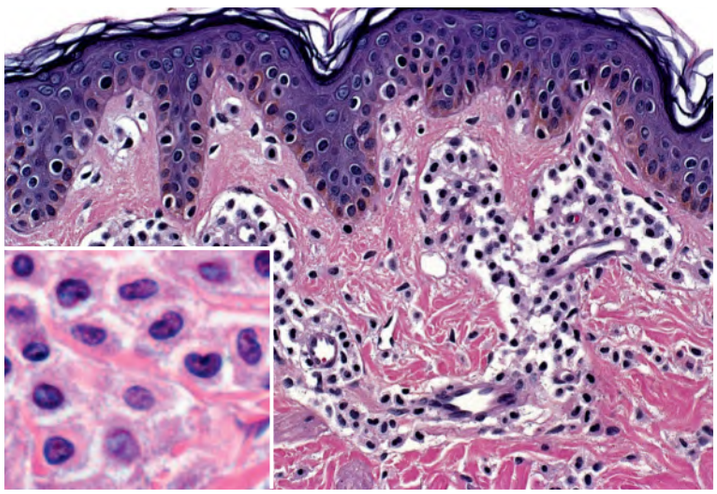

Fig. 118.12 Cutaneous mastocytosis – histologic features. Mast cells within the dermis have a rounded or cuboidal appearance. Granules are seen within the amphophilic cytoplasm (inset). *Courtesy Lorenzo Cerroni, MD.*

TREATMENT

Treatment of patients with mastocytosis is directed primarily at alleviating symptoms, since there is no cure for this disorder. Many patients with cutaneous mastocytosis and ISM have few, if any, symptoms and therefore require little or no therapy. Mastocytosis patients should be provided with information on environmental triggers (e.g. friction, heat) and potential mast cell degranulating agents (Table 118.3)[61]. Systemic anesthetic agents that have been directly or indirectly implicated in precipitating anaphylactoid reactions in mastocytosis patients are also listed in Table 118.3. In contrast, local injections of lidocaine can be used safely in these patients. It has been recommended that mastocytosis patients undergoing general anesthesia be monitored postoperatively for at least 24 hours, since delayed anaphylaxis can occur[62,63].

Antihistamines are often helpful in controlling the symptoms associated with mastocytosis[36,44]. The second-generation antihistamines cetirizine, loratadine, and fexofenadine are preferred because they have longer half-lives and more specific antagonism of the H1 receptor (see Table 18.5). Use of multiple agents and higher than standard doses are often required for symptom control. For example, the author recommends fexofenadine 360 mg in the morning and up to 40 mg of cetirizine at night for control of histamine-related symptoms in adults. In some instances, the addition of an H2 antagonist (e.g. cimetidine, famotidine, nizatidine) may prove beneficial, especially in patients with gastric acid hypersecretion[44].

Oral **cromolyn** sodium (disodium cromoglycate; 400–800 mg/day), a mast cell stabilizer with poor oral absorption, may alleviate GI manifestations and (to a lesser degree) cutaneous and CNS symptoms associated with mastocytosis. Use of topical cromolyn for cutaneous mastocytosis has also been described but has limited efficacy.

Narrowband ultraviolet B or psoralen plus UVA (PUVA) **phototherapy** administered up to four times a week may help to control pruritus and cutaneous whealing in patients with mastocytosis. While this treatment can reduce skin mast cell histamine content, it does not eliminate the mast cell infiltrates[59,64].

Potent topical **corticosteroids**, especially under occlusion for 6 weeks or more, may eliminate pruritus and cutaneous whealing as well as reduce the number of lesional skin mast cells, but this can also lead to skin atrophy[65]. Intralesional injections of triamcinolone acetonide have also been successful in clearing cutaneous mast cell infiltrates. In SM patients, relief of cutaneous and GI symptoms with prednisone alone or in combination with cyclosporine has been described[66]. However, if possible, systemic corticosteroids should be avoided due to the risk of worsening associated osteoporosis. Mastocytosis patients with decreased bone density may benefit from treatment with bisphosphonates or denosumab, a RANK ligand inhibitor[30].

Some patients with severe mastocytosis experience recurrent, life-threatening episodes of hypotension following mast cell mediator release, and therefore should be provided with a premeasured **epinephrine** (adrenaline) preparation (e.g. EpiPen®, Auvi-Q®) for

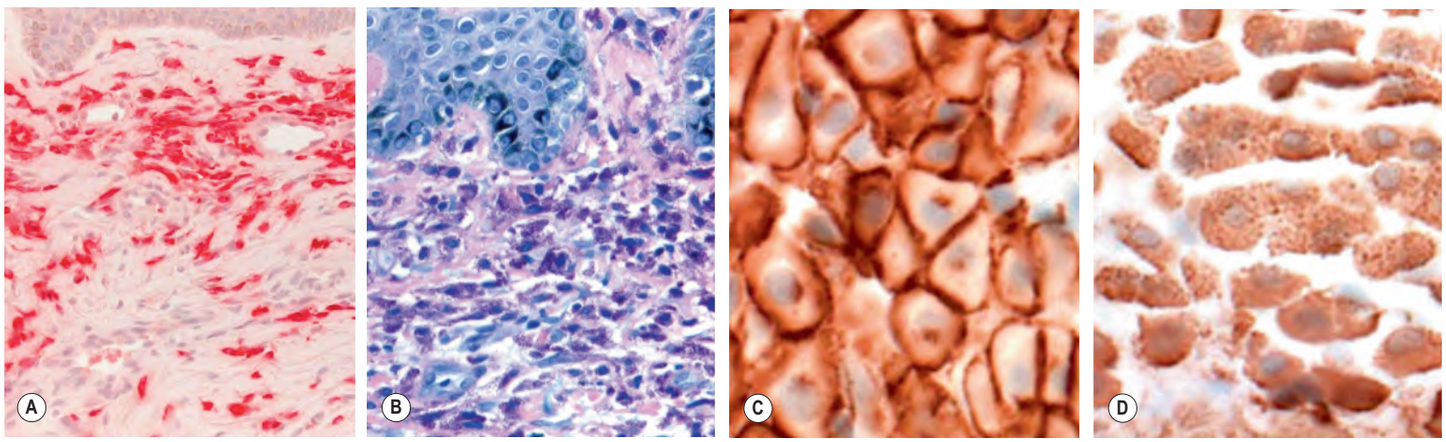

Fig. 118.13 Special stains to detect dermal mast cells. A The Leder method utilizes naphthol AS-D chloroacetate esterase and the mast cell granules appear red. **B** With the Giemsa stain, the mast cell granules stain metachromatically purple. Immunohistochemical staining with monoclonal antibodies that recognize CD117/KIT receptor (**C**) or tryptase (**D**) can also be employed. *A, B, Courtesy Lorenzo Cerroni, MD; C, D, Courtesy Antonio Subtil, MD.*

Downloaded for Anonymous User (n/a) at Egyptian Knowledge Bank from ClinicalKey.com by Elsevier on March 10, 2024. For personal use only. No other uses without permission. Copyright ©2024. Elsevier Inc. All rights reserved.

THERAPEUTIC LADDER FOR MASTOCYTOSIS
Avoidance of relevant mast cell stimuli
Physical
Friction Exercise Heat (e.g. hot bath) or cold (e.g. swimming)
Dietary
Hot beverages Spicy foods Alcohol
Medications
Aspirin Nonsteroidal anti-inflammatory drugs Narcotics (e.g. morphine, codeine) Anticholinergics (e.g. scopolamine) Dextromethorphan (a cough suppressant) Polymyxin B sulfate Some systemic anesthetics, including lidocaine*, d-tubocurarine, metocurine, etomidate, thiopental, succinylcholine hydrochloride (suxamethonium chloride), enflurane, isoflurane (see text for alternatives) Iodine-based radiographic dyes Dextran (in some IV solutions)
Local therapy for symptom control
Potent and superpotent topical corticosteroids, including under occlusion (2) Topical calcineurin inhibitors (3) Intralesional corticosteroids (3) Hydrocolloid dressing (for mastocytoma; 3)
Systemic therapy for symptom control
Oral antihistamines (1) Oral cromolyn sodium (1) Omalizumab (2) Oral PUVA [psoralens plus ultraviolet A] (2) Narrowband ultraviolet B (3) Oral corticosteroids (3) UVA1 (3) Pre-measured epinephrine with auto-injector (EpiPen®, Auvi-Q®) (3)
Systemic therapy for advanced mastocytosis
Midostaurin (2) Avapritinib (2) Imatinib mesylate (non-codon 816 *KIT* mutation; 1) Cladribine (2) Interferon-α-2b (2; limited success) Hematopoietic stem cell transplantation (2)
*Local lidocaine injections are safe; although no large case series exist, systemic anesthetics that have been safely administered to patients with mastocytosis include fentanyl, midazolam, propofol, sufentanil, remifentanil, ketamine, desflurane, sevoflurane, cisatracurium, pancuronium, and vecuronium bromide.

Table 118.3 Therapeutic ladder for mastocytosis. Clinically relevant triggers for mast cell degranulation vary substantially among mastocytosis patients; avoidance of environmental and dietary exposures as well as medications should be approached on an individual basis, considering the patient's previous experiences[61]. Additional tyrosine kinase inhibitors under investigation for the treatment of systemic mastocytosis include repretinib and (for patients with non-codon 816 KIT mutations) masitinib. Key to evidence-based support: (1) prospective controlled trial; (2) retrospective study or large case series; (3) small case series or individual case reports.

emergency use. In some instances, these patients may experience additional similar attacks within hours of the initial event; prednisone 20–40 mg/day for 2–4 days may suppress these recurrent reactions[36,44].

Omalizumab, a humanized murine monoclonal antibody to IgE approved for the treatment of asthma and chronic spontaneous urticaria, has been reported to control symptoms in patients with mastocytosis who are resistant to antihistamine therapy. In a series of 40 adults with cutaneous mastocytosis or ISM, omalizumab (150–300 mg every 2 weeks) induced a >50% reduction in mast cell mediator-related symptoms in 22 patients (55%), with a median time to response of 2 months[2]. In this and most other reports, omalizumab reduced symptoms, but not serum tryptase levels or skin lesions, in mastocytosis patients[2]. However, a 50%–90% reduction in maculopapular lesions was reported in two mastocytosis patients treated with omalizumab (300 mg monthly) for 5–7 months[3]. At present, omalizumab's mechanism of action in mastocytosis remains unclear[2,3].

Multitargeted **tyrosine kinase inhibitors** are capable of limiting proliferation and promoting apoptosis of D816V-expressing mast cells. Among such agents, midostaurin and avapritinib are FDA-approved for the treatment of aggressive SM (including ASM, SM-AHN, and MCL), with overall response rates of ≥60% and ≥75%, respectively, and a median survival of ~30–40 months for midostaurin in this patient group[6,67]. Imatinib mesylate is a tyrosine kinase inhibitor that blocks KIT and PDGF receptors, as well as the BCR-ABL oncoprotein associated with chronic myelogenous leukemia. However, the active site for imatinib within the KIT receptor is proximal to the location affected by the common codon 816 mutations (see Fig. 118.2). The resulting amino acid substitutions impede the binding of imatinib to KIT and thereby negate its potential therapeutic effect[5]. On the other hand, imatinib may alleviate the signs and symptoms of mastocytosis in patients with other *KIT* mutations (e.g. del419, K509I, F522C, V560G; see Fig. 118.2)[5,44,49,67] as well as in those with wild type *KIT* or a myeloproliferative disorder associated with the *FIP1L1–PDGFRA* fusion gene[68]. Other genes mutated in SM and their respective pathways may serve as potential therapeutic targets in the future.

Among chemotherapeutic agents, intravenous cladribine has the most evidence of efficacy in reducing skin lesions and BMMCs in patients with advanced SM, including those with the D816 *KIT* mutation[4,44]. However, a recent registry-based analysis found significantly longer overall and disease-free survival of patients with advanced SM treated with midostaurin compared to those who received cladribine[7]. For patients with SM-AHN, chemotherapy should be directed at the associated hematologic disorder[36,44].

Local radiation therapy with ~20–40 Gy over a 7- to 14-day period may benefit patients with pain due to bone involvement[69]. Splenectomy can be helpful in mastocytosis patients with hypersplenism who experience significant cytopenias and may improve survival in patients with aggressive disease[44,70]. Interferon α-2b has been used with limited success in patients with aggressive forms of mastocytosis[71], and non-myeloablative allogeneic hematopoietic stem cell transplantation has been performed with variable benefit in patients with life-threatening SM[72].

Additional figures available in our eBook (see inside front cover for access code).

REFERENCES

1. Akin C, Valent P. Diagnostic criteria and classification of mastocytosis in 2014. *Immunol Allergy Clin North Am*. 2014;34:207–218.
2. Lemal R, Gouquet G, Terriou L, et al. Omalizumab therapy for mast cell mediator symptoms in patients with ISM, CM, MMAS and MCAS. *J Allergy Clin Immunol*. 2019;7:2387–2396.
3. Hinojosa T, Lewis DJ, Vangipuram R, et al. The efficacy of omalizumab in cutaneous mastocytosis: a case series. *Dermatol Ther*. 2019;32:e12848.
4. Tefferi A, Li CY, Butterfield JH, Hoagland HC. Treatment of systemic mast-cell disease with cladribine. *N Engl J Med*. 2001;344:307–309.
5. Vega-Ruiz A, Cortes JE, Sever M, et al. Phase II study of imatinib mesylate as therapy for patients with systemic mastocytosis. *Leuk Res*. 2009;33:1481–1484.
6. Gotlib J, Kluin-Nelemans HC, George TI, et al. Efficacy and safety of midostaurin in advanced SM. *N Engl J Med*. 2016;374:2530–2541.
7. Lübke J, Schwaab J, Naumann N, et al. Superior efficacy of midostaurin over cladribine in advanced systemic mastocytosis: a registry-based analysis. *J Clin Oncol*. 2022;40:1783–1794.
8. Robinson WA, Quiery AT, Drummond MW. Safety and efficacy of avapritinib in advanced systemic mastocytosis: the phase 1 EXPLORER trial. *Nat Med*. 2021;27:2183–2191.
9. Nettleship ETW. Rare forms of urticaria. *Br Med J*. 1869;2:323–324.

Downloaded for Anonymous User (n/a) at Egyptian Knowledge Bank from ClinicalKey.com by Elsevier on March 10, 2024. For personal use only. No other uses without permission. Copyright ©2024. Elsevier Inc. All rights reserved.

eFig. 118.1 Mastocytoma with blistering and erosion. *Courtesy Julie V. Schaffer, MD.*

eFig. 118.3 Mastocytoma with bulla formation. *Courtesy Theodore Zaki, MD.*

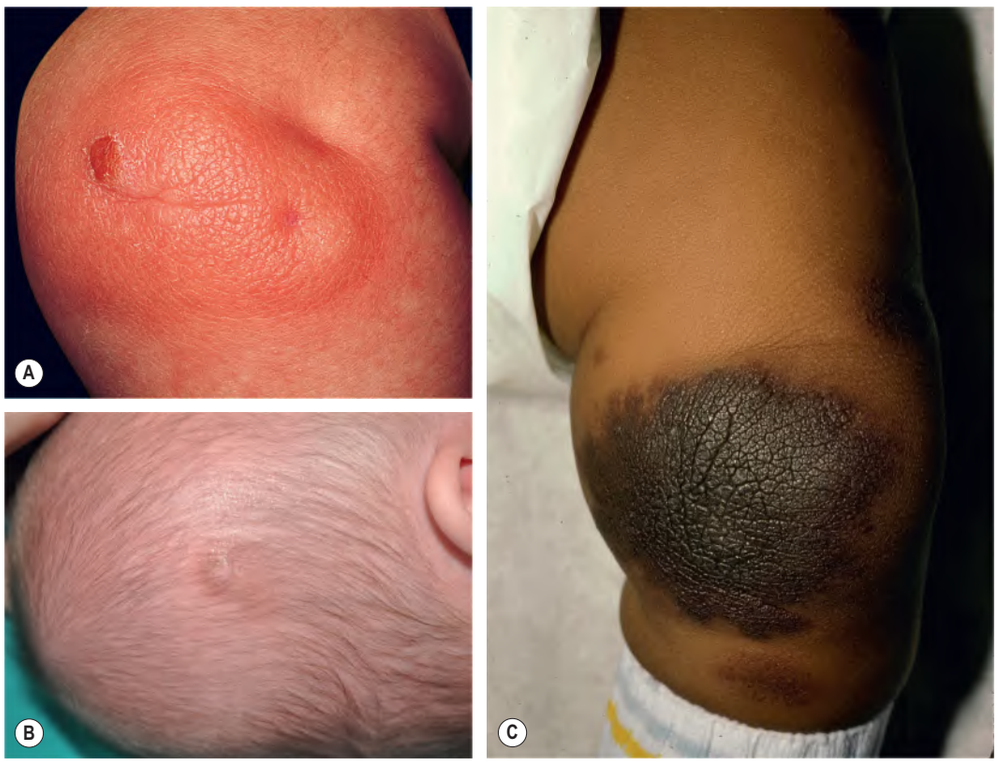

eFig. 118.2 Mastocytomas in infants. A Note the leathery appearance of the skin and erosions. **B** Subtle tan papule on the scalp. **C** Darker brown plaque. *B, Courtesy Antonio Torrelo, MD; C, Courtesy Joyce Rico, MD.*

Downloaded for Anonymous User (n/a) at Egyptian Knowledge Bank from ClinicalKey.com by Elsevier on March 10, 2024. For personal use only. No other uses without permission. Copyright ©2024. Elsevier Inc. All rights reserved.

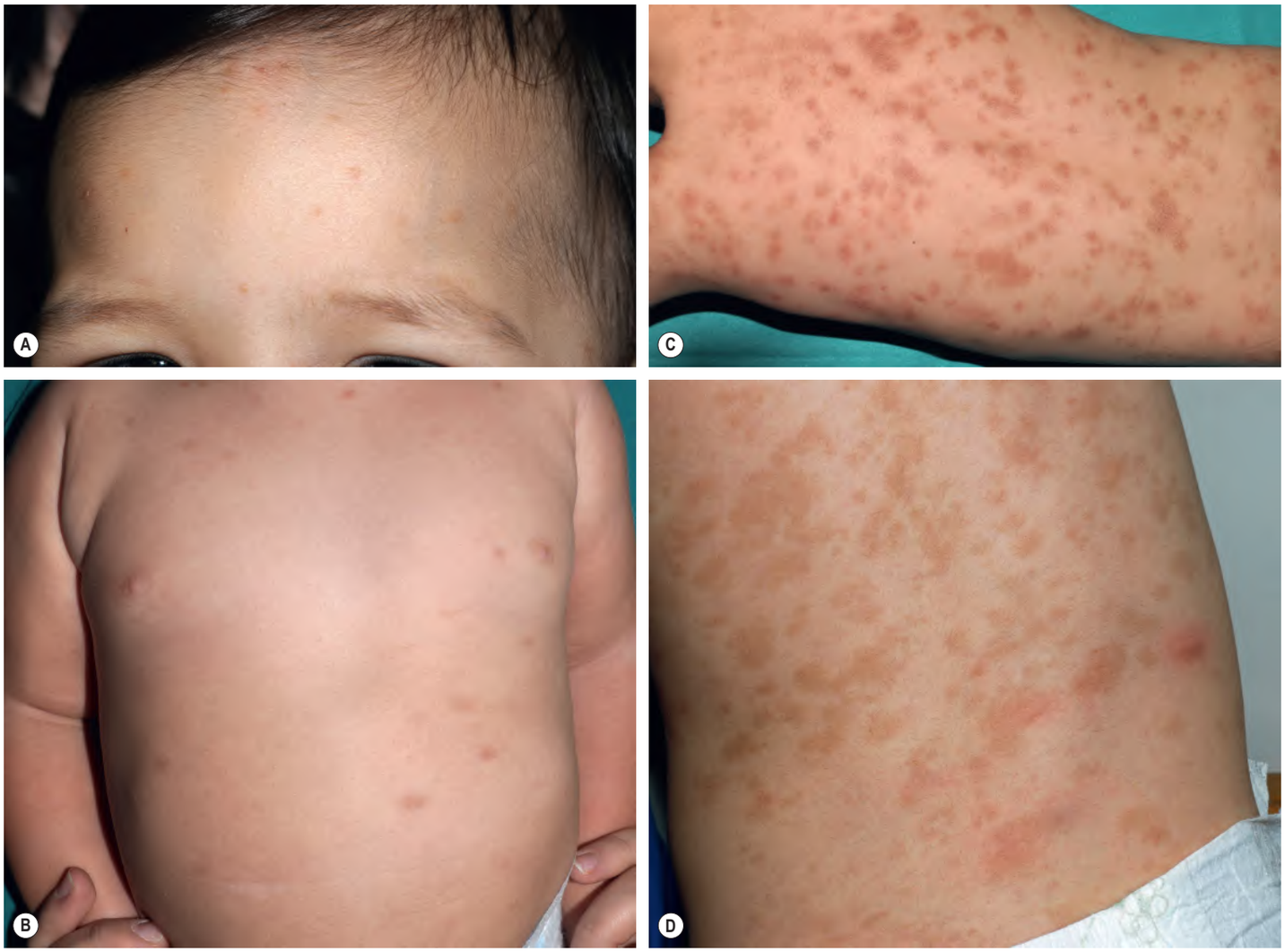

eFig. 118.4 Maculopapular cutaneous mastocytosis in children. A–D Variable numbers of tan to brown macules, papules, and plaques are evident, with monomorphous (**A**) or polymorphous (**B–D**) lesions. *B, C, Courtesy Antonio Torrelo, MD; D, Courtesy Julie V. Schaffer, MD*.

eFig. 118.5 Diffuse cutaneous mastocytosis. Leathery, infiltrated skin with multiple erosions.

eFig. 118.6 Diffuse cutaneous mastocytosis. Thickened skin with a leathery texture in a generalized distribution, with multiple superimposed vesicles and erosions. *Courtesy Julie V. Schaffer, MD*.

Downloaded for Anonymous User (n/a) at Egyptian Knowledge Bank from ClinicalKey.com by Elsevier on March 10, 2024. For personal use only. No other uses without permission. Copyright ©2024. Elsevier Inc. All rights reserved.

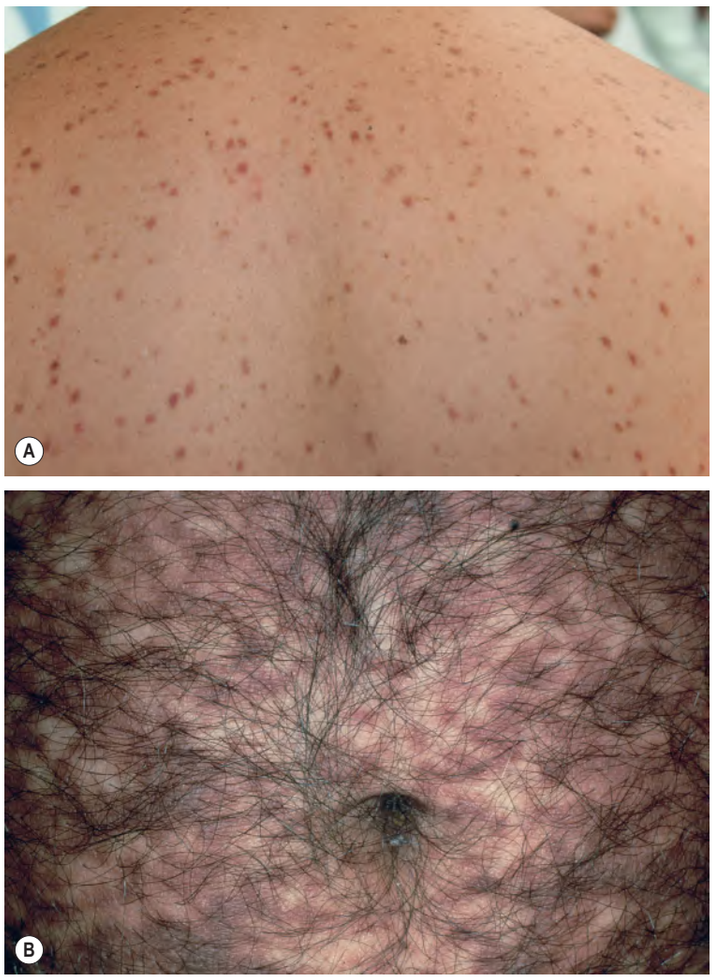

eFig. 118.7 Adult maculopapular mastocytosis ("urticaria pigmentosa"). Multiple small (**A**) and (**B**) larger, confluent red–brown papules and plaques.

eFig. 118.8 Adult maculopapular mastocytosis ("urticaria pigmentosa"). Numerous reddish-brown macules and papules that were present on the extremities and the trunk. The patient had a normal serum tryptase level. *Courtesy Jonathan S. Leventhal, MD.*

Downloaded for Anonymous User (n/a) at Egyptian Knowledge Bank from ClinicalKey.com by Elsevier on March 10, 2024. For personal use only. No other uses without permission. Copyright ©2024. Elsevier Inc. All rights reserved.